

Cytokine-Induced Neurogenesis and Angiogenesis Reversed Cognitive Decline in a Vascular Dementia Patient with Hashimoto's Thyroiditis

Case Report

DOI: 10.59152/ESJCR/1036

Takuji Shirasawa^{1,*}, Luis Carlos Aguilar Cobos²

¹Ochanomizu Health and Longevity Clinic, Tokyo, Japan

²Livant Neurorecovery Center, Guadalajara, Mexico

Received: April 19, 2023; **Accepted:** April 24, 2023; **Published:** April 26, 2023

***Corresponding author:** Takuji Shirasawa, Ochanomizu Health and Longevity Clinic, Tokyo, Japan,
e-mail: shirasawa@shirasawa-acl.net.

Copyright: © 2023 Takuji Shirasawa. This is an open-access article distributed under the terms of the Creative Commons Attribution License, which permits unrestricted use, distribution, and reproduction in any medium, provided the original author and source are credited.

Abstract

Vascular dementia (VaD) is the second most prevalent cause of dementia in the world after Alzheimer's disease (AD), but no curative treatment has yet been established. We treated a 70-year-old male Japanese VaD patient with Hashimoto's thyroiditis using cytokine-induced neurogenesis and angiogenesis to regenerate residual neuronal stem cells and degenerated middle cerebral artery (MCA) branches. This treatment successfully regenerated the atrophied cerebral cortex, hippocampus, and degenerated MCA branches and was associated with improved cognitive function and the resolution of electrophysiological abnormalities. To the best of our knowledge, this is the first case report to demonstrate that cytokine-induced neurogenesis and angiogenesis reversed cognitive decline due to VaD.

Keywords

Vascular Dementia (VaD), Cytokine, Hashimoto's Thyroiditis, Neurogenesis, Angiogenesis

Introduction

Vascular dementia (VaD) is the second most prevalent cause of dementia in the world after Alzheimer's disease (AD) [1]. VaD constitute of heterogeneous neurological conditions in which the decline of cognitive functions is associated with structural and functional alterations in the cerebral vasculature [1]. Systemic autoimmune disorders such as systemic lupus erythematosus, rheumatoid arthritis, and antiphospholipid syndrome can be associated with VaD, but the association with Hashimoto's thyroiditis has not been reported [2]. Various therapeutic approaches have been applied for VaD, but no promising treatments have been reported [3]. The use of regenerative approaches for VaD has also been explored, but preclinical trials such as a treatment targeting TGF-

beta signaling in the brain are still in the early phase [4]. However, a recent pathological study clearly detected neuronal precursor cells in the hippocampus of 18 participants with a mean age of 90.6 years, including persons with MCI and Alzheimer's disease, suggesting that hippocampal neurogenesis persists in aged and diseased human brains [5]. In previous publications, we explored the possibility of using cytokines that induce neurogenesis to regenerate atrophied brains in patients with AD and frontotemporal dementia (FTD) and showed that a combination of cytokines such as hepatocyte growth factor (HGF), granulocyte colony stimulating factor (GCSF), insulin-like growth factors (IGFs), and progranulin (PGRN) successfully regenerated the atrophied hippocampus of

patients with AD and FTD, reversing cognitive declines [6,7]. However, a clinical application of cytokine treatment for VaD has not yet been reported. In the present case report, we provide evidence that cytokine-induced neurogenesis and angiogenesis can reverse cognitive decline in VaD patients with Hashimoto's thyroiditis.

Hashimoto's thyroiditis is an autoimmune illness in which thyroid cells are damaged by immune cells and antibodies; this illness has various symptoms, although the causes have not been elucidated [8]. Interestingly, brain perfusion defects were observed in patients with Hashimoto's thyroiditis without neurological symptoms, suggesting that in Hashimoto's disease, autoantibodies either induce encephalitis or vasculitis in the brain [9]. In the present report, we suggest that Hashimoto's thyroiditis is one of the causative mechanisms for the development of VaD.

Case Presentation

A 70-year-old Japanese man developed gradual progression of memory dysfunction with well-preserved language comprehension, emotional control, and spatial and temporal orientation. His score on the Mini-Mental State Examination (MMSE) at his first visit to our clinic on June 11, 2019, indicated minimal cognitive impairment (MMSE score = 28/30) with mild memory impairment. Emotional control and language comprehension were well preserved. Apoprotein E (APOE) genotype analysis showed that he was a $\epsilon 4/\epsilon 3$ heterozygous carrier. Cognitive function examination on June 12, 2018, using Cognitrix revealed verbal memory impairment (Cognitrix score=62), while reaction times, motor speed, sustained attention, cognitive flexibility, executive function, reasoning, and working memory were normal (Figure 1). MRI data acquired on June 11, 2019, showed moderate atrophy of the cerebral cortex in the temporal lobe and mild atrophy in the frontal and parietal lobes (Figure 2A). A cross-sectional cortical image of the right temporal lobe revealed reductions in both gray matter volume and white matter volume, with an enlarged sulcus and degenerated cortical structures (Figure 2C). An *in silico* endoscopic view of the right hippocampus showed that the central part of the anterior right hippocampus exhibited moderate atrophy (Figure 2E). MRA data acquired on June 11, 2019, showed severe degenerative changes with perforators from the left MCA as well as the right MCA (Figure 3A, 3C). A cross-sectional image of the inferior trunk of the right MCA and middle temporal

branch (MTm) revealed that the MTm had a degenerated and occluded artery compared with that of the inferior trunk of the MCA (Figure 3E). P300 EEG data analyzed by Neuroscan Software showed that after the target stimulus (high-pitched sound), asymmetrical low-voltage P300 responses were detected at the frontopolar, frontal, central, temporal, parietal, and occipital leads (Figure 4A, red line), which is compatible with MRA abnormalities, as shown in Figure 3. The left frontal lead showed a P300 response with a lower voltage of $8 \mu V^2$ and a premature peak at 240 ms (Figure 4B, red line in left panel). The right frontal lead also showed a symmetrical P300 response (Figure 4B, red line in right panel), suggesting vascular pathology in the frontal, temporal, parietal, and occipital lobes. Coherence analysis of the P300 indicated that frontal leads showed asymmetries (data not shown). Flash visual evoked potentials showed moderate dissociation between FP1 and PF2 leads (Figure 4D, left panel), suggesting that vascular pathologies were dominantly involved in the degeneration of the temporal, frontal and parietal cerebral cortex (Figure 4A). Blood chemistry, CBC, and HbA1c analyses failed to indicate any disorder associated with dementia. However, we detected hypothyroidism according to levels of free T4 (1.25 ng/dL), free T3 (1.87 pg/mL), TSH (11.30 μ IU/mL), anti-TPO antibody (28 IU/mL), and anti-thyroglobulin antibody (8,310 IU/mL), suggesting hypothyroidism due to Hashimoto's thyroiditis. We therefore diagnosed this patient as having vascular pathology associated with Hashimoto's thyroiditis based on clinical symptoms, thyroid function, morphological abnormalities, and electrophysiological abnormalities.

We treated the patient with a cytokine cocktail containing hepatocyte growth factor (HGF), granulocyte colony stimulating factor (GCSF), adiponectin, insulin-like growth factor-1 (IGF-1), and IGF-2 from June 11, 2019, to October 26, 2020. We then added additional cytokines, vascular endothelial growth factor (VEGF) and progranulin from October 26, 2020, to February 26, 2021 (Figure 1), in addition to thyroid hormone. The clinical protocol used in this study as well as the cytokine cocktail formulation was designed and developed by Luis Carlos Aguilar Cobos in the Livant Neurorecovery Center, Mexico, as described previously [6]. On February 26, 2021, twenty months after cytokine cocktail treatment, the patient's verbal memory function, which had previously been impaired, exhibited recovery, with a concomitant improvement in MMSE score (from 25/30 to 27/30) (Figure 1). The patient's cognitive

functions further improved in terms of working memory, verbal memory, attention, executive function, motor speed, and cognitive flexibility, while reasoning and reaction time were maintained, as illustrated in Figure 1.

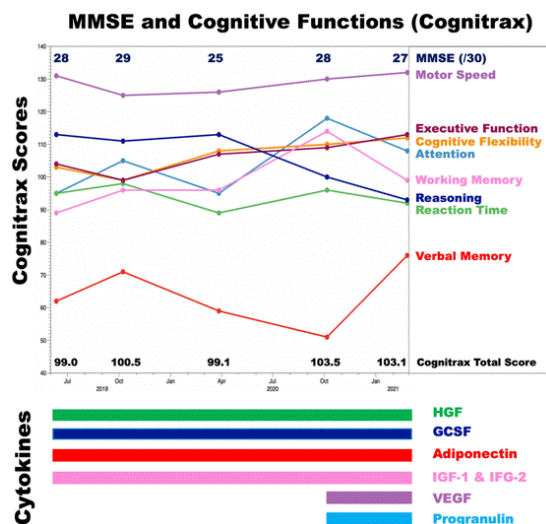


Figure 1: MMSE scores and cognitive function before and after cytokine-induced neurogenesis and angiogenesis.

Cognitive functions were evaluated by CognitrixR and the Mini-Mental State Examination (MMSE) at five timepoints: June 11, 2019, October 8, 2019, March 27, 2020, October 6, 2020, and February 26, 2021. The MMSE scores are shown in the upper part of the graph. Cognitrix scores for working memory (magenta), attention (light blue), reasoning (dark blue), motor speed (plum), cognitive flexibility (orange), executive function (brown), and verbal memory (red) are shown chronologically. Administered cytokines are shown under the graph.

We reevaluated the patient's EEG signals, which showed a significant decrease in slow waves, on February 26, 2021. P300 EEG responses were significantly improved with a higher voltage and symmetrical P300 in all brain areas, including the frontal, temporal, parietal, and occipital lobes (Figure 4A, black lines), suggesting that inhibitory GABAergic interneurons as well as excitatory glutamatergic neurons were regenerated globally to reconstruct the functional neuronal networks in the cerebral cortex, as suggested previously [6]. Higher magnification of P300 responses in the left frontal leads clearly showed that the low-voltage P300 at 240 ms, at $7 \mu V^2$ before treatment, significantly improved to a normal P300 response at 480 ms with $30 \mu V^2$ after treatment (Figure 4B, left panel). Another improvement was observed in the right frontal leads (Figure 4B, right panel). A similar improvement was observed in the parietal lobe, with a symmetrical high-voltage P300 (Figure 4C). The dissociations of flash visual

evoked potentials between FP1 and FP2 on June 11, 2019, were significantly improved on February 26, 2021 (Figure 3D), indicating that cytokine-induced neurogenesis and angiogenesis were physiologically relevant for the processing of visual stimuli.

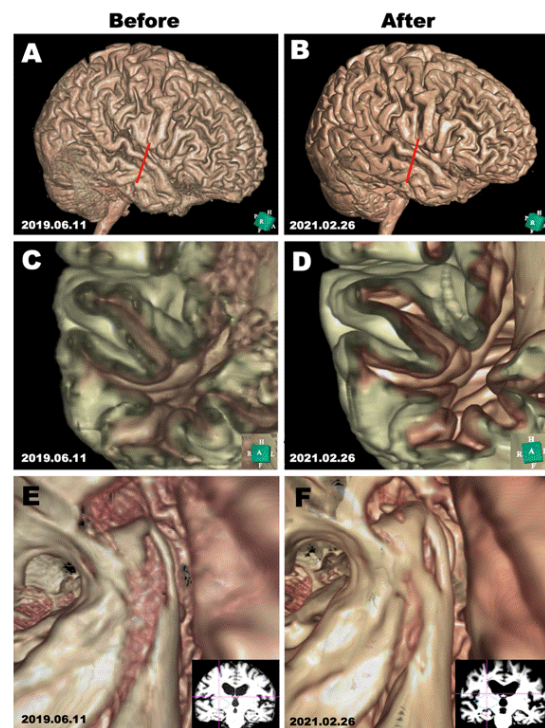


Figure 2: Morphological evaluations before and after cytokine-induced neurogenesis.

MRI scans were performed on June 11, 2019, and on February 26, 2021, before and after cytokine cocktail treatment. **A, B:** 3D structure of the cerebral cortex reconstructed in silico using Expert INTAGER software from MRI T1-weighted images with 1-mm sagittal slices before and after cytokine cocktail treatment. **C, D:** Cross-sectional images of the superior temporal lobe (as indicated by red lines in A and B) show the regeneration of the atrophied cerebral cortex. **E, F:** Endoscopic in silico views of the right hippocampus show the regeneration of the atrophied right hippocampus after cytokine cocktail treatment.

We performed MRI on February 26, 2021, which showed a slight increase in the volume of the atrophied gyrus in the temporal cortex after treatment (Figure 2B). The cross-sectional image of the recovered gyrus showed increased gray matter volume and white matter volume with an enlarged gyrus and normal cortical structure (Figure 2D). Vascular pathologies detected on June 11, 2019, were absent in an endoscopic in silico view of the same cortex recorded on October 26, 2021 (Figure 2D). Another endoscopic in silico view showed that the atrophied right hippocampus had significantly regenerated, with a smaller hole-like lesion in the anterior part of the hippocampus

after treatment (Figure 2H); this change is clinically compatible with recovered memory functions (Figure 1).

We then reevaluated the MRA data on February 26, 2021. MRA data collected on June 11, 2019, exhibited degenerative vascular pathologies in the MCA and perforant branches from the MCA (Figure 3A, 3C). MRA data collected on February 26, 2021, clearly showed significant angiogenesis of the perforator from the MCA (Figure 3B, 3D), suggesting that the improvement in blood supply induced not only the regeneration of damaged brain tissue but also rescued neurophysiological activity for normal cognitive function. The cross-sectional image of the small artery of the MTm exhibited regeneration of vascular structures, including endothelial cells, smooth muscles, and adventitial tissues (Figure 3F).

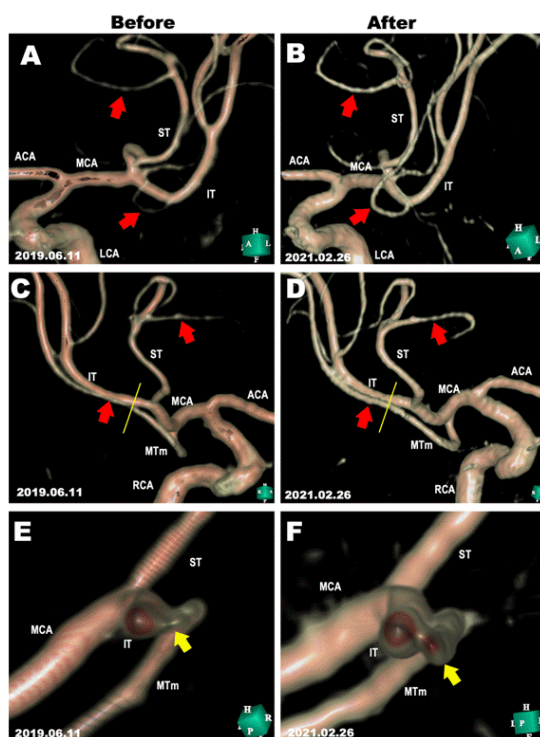


Figure 3: Morphological evaluations of the MRA before and after cytokine-induced angiogenesis.

MRA images on June 11, 2019, and on February 26, 2021, before and after cytokine cocktail treatment. **A, B:** The left middle cerebral artery (MCA) before and after cytokine cocktail treatment. Regenerated perforant branches are indicated by red arrows. **C, D:** The right middle cerebral artery (MCA) before and after cytokine cocktail treatment. Regenerated perforant branches are indicated by red arrows. **E, F:** Cross-sectional images of the IT branch and MTm branch of the MCA (cut position is indicated by yellow lines in C and D) before and after cytokine cocktail treatment. MTm branches are indicated by yellow arrows.

ACA, anterior cerebral artery; IT, inferior trunk of MCA; LCA, left carotid artery; MCA, middle cerebral artery; MTm, middle temporal branch; RCA, right carotid artery; ST, superior trunk of MCA.

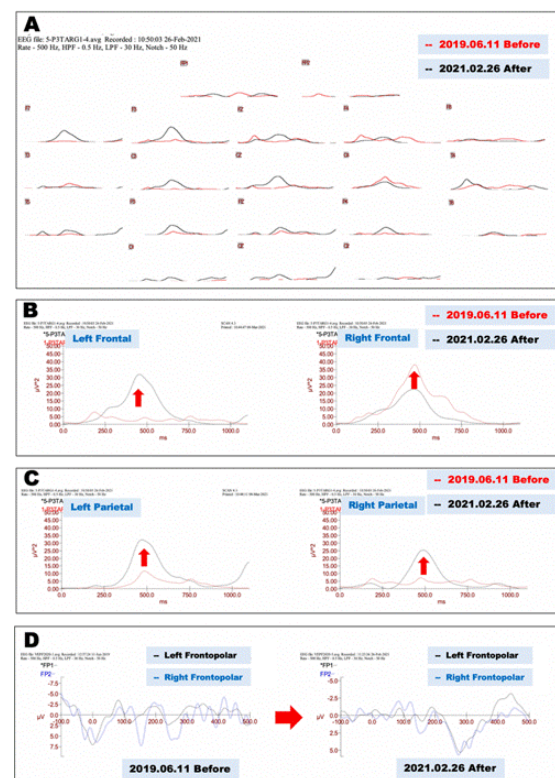


Figure 4: Neurophysiological evaluations before and after cytokine treatment.

A. Electrophysiological evaluation of P300 EEG responses before and after cytokine-induced neurogenesis and angiogenesis. Before-treatment (June 11, 2019) P300 EEG responses are shown as red lines, and after-treatment (February 26, 2021) EEG responses are shown as black lines.

B. Magnification of recordings from frontal leads in Fig. 4A show that the asymmetrical P300 recorded on June 11, 2019 (red lines) significantly improved and became symmetrical in recordings from both frontal leads on February 26, 2021 (black lines; left, left frontal leads; right, right frontal leads).

C. Magnification of recordings from parietal leads in Fig. 4A show that the low-voltage P300 recorded on June 11, 2019 (red lines) significantly improved and became a symmetrical high-voltage P300 response in recordings from both parietal leads on February 26, 2021 (black lines; left, left parietal leads; right, right parietal leads).

D. Electrophysiological records of flash visual evoked potentials before and after cytokine treatment. Asymmetrical potentials were recorded on June 11, 2019 between FP1 (left frontopolar leads, black line) and FP2 (right frontopolar leads, blue line); these potentials were improved on February 26, 2021 (right panel).

Discussions

In the present case report, we demonstrate for the first time that cytokine-induced neurogenesis and angiogenesis regenerated not only the hippocampus and cerebral cortex

but also the degenerated small artery branches from the MCA in a VaD patient with Hashimoto's thyroiditis. These improvements were associated with the reversal of cognitive decline in working memory, verbal memory, attention, cognitive flexibility and executive function. Neurophysiological assessment clearly showed that cortical neural networks exhibited multifocal impairment in the cerebral cortex due to vascular pathologies (Figure 4). Although the patient was an APOE $\epsilon 4/\epsilon 3$ heterozygous carrier, we failed to detect premature P300 responses in the neurophysiological evaluation (Figure 4A, 4B) and also atrophy of the cerebral cortex was dominant in temporal lobe that is not typical for AD pathology (Figure 2); thus, we suggested that the contribution of AD was minimal, and the majority of dementia pathology is attributable to vascular pathology. In the present study, we report for the first time that cytokine treatment also induced the regeneration of degenerated small branches from the MCA (Figure 3) with concomitant improvements in P300 symmetry (Figure 4) and cognitive functions (Figure 1). As previously reported, Hashimoto's thyroiditis may be complicated with encephalitis as well as vasculitis of cerebral arteries in some instances [9]. The patient showed an extraordinarily high titer of anti-thyroglobulin antibody (8,310 IU/mL), implying that Hashimoto's thyroiditis was induced by a specific antigen. Intriguingly, the patient worked with metallic samarium (Sm), a rare metal used for alloy chemistry, which may play a role as a hapten for anti-thyroglobulin antibody.

Among the 221 dementia patients who visited our clinic from March 2018 to March 2023, 112 patients were diagnosed with VaD or mixed VaD with AD, of whom 25 had Hashimoto's thyroiditis. These 25 patients were either anti-thyroglobulin antibody-positive or anti-thyroid peroxidase (TPO) antibody-positive. Interestingly, the majority of patients with Hashimoto's thyroiditis showed similar degenerative changes in MCA branches. Autoimmune-associated vasculitis develops into ischemic stroke with hemorrhagic transformation [10], suggesting that anti-thyroglobulin antibodies may cause the cluster of vascular pathologies that lead to dementia, as shown in the present case study. Regarding cytokines in the treatment, we applied adiponectin for the protection of endothelial cells, since adiponectin protected against the occlusion of the MCA in rats with type 2 diabetes mellitus [11]. We also applied VEGF from October 6, 2020, to February 26, 2021; in this interval, the patient exhibited

improvements in verbal memory, executive function, and cognitive flexibility associated with the regeneration of MCA branches. Angiogenesis may be induced by VEGF in pathological conditions such as brain ischemia, as shown previously [12]. Progranulin may also play an important role in the recovery of memory and frontal lobe functions by enhancing the neurogenesis of the frontal and temporal lobes, as shown in a mouse model of ischemia [6,13]. It is important to combine two kinds of cytokines: HGF, GCSF, IGFs and progranulin for neurogenesis and VEGF and adiponectin for angiogenesis as shown in Figure 1. Clinical application of cytokine-induced neurogenesis and angiogenesis for VaD is still in the early phase, but thus far, we have administered the cytokine cocktail treatment to 112 patients with VaD and 25 patients with Hashimoto's thyroiditis; neurogenesis and angiogenesis were observed in the majority of VaD patients (unpublished data). We believe that cytokine-induced neurogenesis and angiogenesis is the most promising clinical strategy to reverse cognitive decline due to VaD.

Conclusions

Vascular dementia (VaD) is a progressive neurodegenerative disease for which no curative treatment has yet been established. This is the first case report to demonstrate that cytokine-induced neurogenesis and angiogenesis reversed cognitive decline due to VaD. In this case report, we explored the possibility that cytokine treatment is a novel strategy for treating VaD.

Acknowledgement

The authors thank Ms. Sayuri Sato, Ms. Masami Fukuda, and Ms. Fernanda Diaz for assistance in the preparation of this manuscript.

Informed Consent

Written informed consent was obtained from the patient.

Conflict of Interest

The authors declare that they have no conflicts of interest.

References

1. Lecordier S, Manrique-Castano D, El Moghrabi Y, El Ali A. Neurovascular Alterations in Vascular Dementia: Emphasis on Risk Factors. *Front Aging Neurosci.* 2021; 13: 727590.
2. Atzeni F, Pipitone N, Iaccarino L, Masala IF, Weiss R, Alciati A, et al. Rheumatic diseases and autoimmune vascular dementia. *Autoimmun Rev.* 2017; 16(12): 1265-1269.

3. Kuang H, Zhou ZF, Zhu YG, Wan ZK, Yang MW, Hong FF, et al. Pharmacological Treatment of Vascular Dementia: A Molecular Mechanism Perspective. *Aging Dis.* 2021; 12(1): 308-326.
4. Kandasamy M, Anusuyadevi M, Aigner KM, Unger MS, Kniewallner KM, de Sousa DMB, et al. TGF-beta Signaling: A Therapeutic Target to Reinstates Regenerative Plasticity in Vascular Dementia? *Aging Dis.* 2020; 11(4): 828-850.
5. Tobin MK, Musaraca K, Disouky A, Shetti A, Bheri A, Honer WG, et al. Human Hippocampal Neurogenesis Persists in Aged Adults and Alzheimer's Disease Patients. *Cell Stem Cell.* 2019; 24(6): 974-982.
6. Shirasawa T, Cobos LCA. Cytokine-induced Neurogenesis for Alzheimer's Disease and Frontotemporal Dementia. *Personalized Medicine Universe.* 2022; 11: 27-32.
7. Shirasawa T, Cobos LCA. Cytokine-induced Neurogenesis Can Reverse Cognitive Decline in Alzheimer's Disease. *Mathew Journal of Case Report.* 2023; 8(3): 1-7.
8. Yuan J, Qi S, Zhang X, Lai H, Li X, Xiaoheng C, et al. Local symptoms of Hashimoto's thyroiditis: A systematic review. *Front Endocrinol (Lausanne).* 2022; 13: 1076793.
9. Zettinig G, Asenbaum S, Fueger BJ, Hofmann A, Diemling M, Mittlboeck M, et al. Increased prevalence of subclinical brain perfusion abnormalities in patients with autoimmune thyroiditis: evidence of Hashimoto's encephalitis? *Clin Endocrinol (Oxf).* 2003; 59(5): 637-643.
10. Uppal S, Goel S, Randhawa B, Maheshwary A. Autoimmune-Associated Vasculitis Presenting as Ischemic Stroke With Hemorrhagic Transformation: A Case Report and Literature Review. *Cureus.* 2020; 12(9): e10403.
11. Wang M, Li Y, Zhang R, Zhang S, Feng H, Kong Z, et al. Adiponectin-Transfected Endothelial Progenitor Cells Have Protective Effects After 2-Hour Middle-Cerebral Artery Occlusion in Rats With Type 2 Diabetes Mellitus. *Front Neurol.* 2021; 12: 630681.
12. Ahmad A, Nawaz MI. Molecular mechanism of VEGF and its role in pathological angiogenesis. *J Cell Biochem.* 2022; 123(12): 1938-1965.
13. Liu Y, Ren J, Kang M, Zhai C, Cheng Q, Li J, et al. Progranulin promotes functional recovery and neurogenesis in the subventricular zone of adult mice after cerebral ischemia. *Brain Res.* 2021; 1757: 147312.