

Case Report and Literature Review: A Severe Case of Pyoderma Gangrenosum Approached with Regenerative Medicine

Case Report

DOI: 10.59152/ESJCR/1043

Yomira N Ortiz-Avilez¹, Perla Palafox-Herrera¹, Siddhartha Palacios², Selem Torres¹, Miguel Ramirez-Amezcu¹, Diana Esquivel^{1,3*}

¹Instituto de Terapia Celular, Mexico

²Clinic Yolia, Mexico

³Global Institute of Stem Cell and Research, Mexico

Received: August 30, 2023; **Accepted:** September 07, 2023; **Published:** September 13, 2023

***Corresponding author:** M.Sc. Diana Esquivel, Head of the laboratories of GIOSTAR, Mexico.

Copyright: © 2023 M.Sc. Diana Esquivel. This is an open-access article distributed under the terms of the Creative Commons Attribution License, which permits unrestricted use, distribution, and reproduction in any medium, provided the original author and source are credited.

Abstract

Pyoderma gangrenosum (PG) is a challenging autoinflammatory neutrophilic dermatoses (ND) condition characterized by painful skin alterations leading to ulceration and tissue necrosis. Regenerative medicine (RG) offers promising strategies for addressing these challenges. Diverse therapies including mesenchymal stem cells (MSC), MSC-exosomes, tilapia skin grafts with fibroblast growth factors (FGF), and antioxidants like Vitamin C (VitC), have demonstrated effectiveness in promoting wound healing, reducing inflammation, and restoring tissue function. This paper offers comprehensive insights into the pathogenesis, epidemiology, and conventional treatment approaches for PG, while also providing a concise review of pertinent RM therapies. In this case report, a severe case of PG is managed with a combination of RM therapies, with remarkable results. A 73-year-old patient experienced persistent ulceration, pain, and edema despite conventional treatments. The administration of IV (Intravenous) MSCs, MSC-exosomes, tilapia skin graft, FGF, and VitC resulted in significant improvement in wound healing, pain reduction, and inflammation control. This case demonstrates the potential use of RM therapies in managing complex dermatological conditions like PG. The integration of regenerative approaches provides hope for patients with challenging conditions, potentially leading to enhanced outcomes and reduced recovery times. As PG remains a difficult-to-treat condition, RM holds promise as a valuable alternative therapy option for patients facing these severe dermatoses conditions.

Keywords

Exosomes, Fibroblast Growth Factors, Mesenchymal Stem Cells, Pyoderma Gangrenosum, Tilapia Skin Graft.

Abbreviations

AD-MSCs: Adipose Tissue-Derived Mesenchymal Stem Cells; EV: Extracellular Vesicles; FGFRs: Fibroblast Growth Factor Receptors; FGF: Fibroblast Growth Factors; ITC: Instituto de Terapia Celular; IL: Interleukins; IV: Intravenous; MSCs: Mesenchymal Stem Cells; ND: Neutrophilic Dermatoses; NSAID: Non-Steroidal Anti-Inflammatory Drugs; PG: Pyoderma Gangrenosum; RM: Regenerative Medicine; Th: T Cell Helper; TNF- α : Tumor Necrosis Factor-Alpha; VEGF: Vascular Endothelial Growth Factor; VitC: Vitamin C.

Introduction

Pyoderma gangrenosum (PG) is generally described as an autoinflammatory neutrophilic dermatoses (ND) condition. This complex skin condition involves painful alterations in the skin, characterized by the emergence of an inflammatory papule, nodule, or even a pustule. These dermatoses usually lead to a purulent-based ulcer, typically characterized by an irregular shape, swollen edges, and in severe cases tissue necrosis [1]. The underlying mechanisms behind these types of lesions is the overreaction of the immune system, even without any

infectious process triggered. It has been observed that patients with ND often possess genetic variations within some of the autoinflammatory-associated genes; which has led to the hypothesis that PG represent a range of polygenic autoinflammatory conditions. Due to clinical overlap with other conditions and absence of defining histopathological and laboratory findings, PG appears as one of the most challenging condition among the ND scenarios [2].

The worldwide incidence estimated for PG is 3-10 per million inhabitants per year, mostly observed in the adult population with a peak of occurrence between the ages of 30 and 50 [3]. A similar incidence has been estimated in Mexico, affecting more frequently women between the ages of 20 and 50. Interestingly, 68% of these cases were derived from other underlying immune-mediated diseases, such as inflammatory bowel disease, Crohn disease, rheumatoid arthritis, hematological malignancies, among others. [2,4]. Due to the rarity of PG, establishing an effective treatment approach has been challenging.

Although the understanding of the pathogenesis of PG remains incomplete, evidence suggests that it involves a complex interplay of dysregulated components of both the innate, and adaptive immune system, along with genetic predisposition [5]. According to recent investigations, one hypothesis suggests that PG is primarily a T-cell-mediated disease that targets follicular adnexal structures; while a second idea proposes that it is a complement pathway-mediated condition with hyperactivation protein complement component (C5a). Although PG is classified as a neutrophilic dermatosis, with these cells predominating in the established histopathology of the disease, it remains unclear whether neutrophils are the primary causative cell type in its development [6]. After antigen priming in individuals who are genetical predisposed, there is a bias toward T cell helper (Th)17/Th1 immune response [7]; which results in the creation of a self-sustained neutrophil-dominated environment, causing general body inflammation. This inflammation is characterized by increased levels of tumor necrosis factor-alpha (TNF- α) and proinflammatory interleukins (IL), such as IL-1 β , IL-1 α , IL-8, IL-12, IL-15, IL-17, IL-23, and IL-36 [8]. Although the release of cytokines combined with a genetic predisposition can be sufficient to initiate PG, various components of the immune system, including the complement system (specifically the neutrophil-attracting C5a), imbalance of regulatory T-cells, B cells, fibroblasts, monocytes/macrophages, and even trauma-mediated cytokine release, can contribute to the complex pathophysiology of this condition [2,6].

The conventional treatment approach to most cases of PG is the administration of systemic drugs, such as cyclosporine, infliximab and glucocorticoids; which attempt to dampen the immune system and reduce the

inflammatory response [1]. However, the severity of the wound along with various metabolic disorders and chronic conditions, add complexity to the healing process, often resulting in a prolonged recovery period ranging from weeks to months. Despite the advancements in medical treatment, the prognosis of PG remains uncertain and, if left untreated, it can be fatal [9]. Therefore, a novel therapy approach is necessary to restore the immune system balance and facilitate tissue regeneration, especially in severe cases of PG.

In recent years, there has been a notable advance in the regenerative medicine (RM) field, which is based on the stimulation of the own patient's cellular complex in order to restore normal function of tissue and organs. Although the use of stem cells is one of the most researched approach in RM, other therapies have received great attention in the last decade. The administration of biostimulatory factors, such as exosomes derived from mesenchymal stem cells (MSCs) [10,11], growth factors [12] and antioxidants [13] have proven to promote the healing process on a cellular level. These innovative approaches have demonstrated favorable outcomes in the treatment of various skin-related conditions, including severe burns, chronic wounds, dermatitis, and diabetic foot. Moreover, the combination of MSC with other RM therapies such as MSC-exosomes [14] and fibroblast growth factors (FGF) [15] appear as a promising synergy therapy. Of special interest, the RM therapy in a skin defect model that combines human MSCs and FGF has demonstrated accelerated cutaneous wound healing [16].

Given that most of the approaches used to treat PG are largely based on case report studies and anecdotal experiences [2], the need for new effective treatments especially in complicated cases of PG is clear. In this case report, we present a concise review of pertinent RM therapies, along with the favorable results of a severe case of PG treated using these procedures. The patient provided written consent for the use of their data and information presented here.

Regenerative approaches

On recent years, biomedical applications of MSC have garnered significant attention in the field of RM as they can be easily harvested from various sources, such as bone marrow, adipose tissue, placental tissue, dental pulp, among others. Likewise, their ability to differentiate into multiple cell types, ease of isolation and characterization, as well as their capacity to migrate to the sites of injury once inside the body, poses MSCs as a valuable therapeutic resource [16]. MSCs are involved in all phases during the wound healing process through immunological modulation and production of growth factors, which improve neovascularization and re-epithelialization, stimulate angiogenesis, and accelerate wound closure [14]. Among

their origins, Adipose Tissue-Derived Mesenchymal Stem Cells (AD-MSCs) can promote wound healing and trigger neovascularization through their ability to differentiate into endothelial cells and release of vascular endothelial growth factor (VEGF); which stimulates the survival, proliferation, and motility of endothelial cells, initiating the formation of new capillaries [17]. AD-MSCs have been reported to have effects on human dermal fibroblasts by increasing collagen synthesis and promoting cellular proliferation [18], suggesting that AD-MSCs could be used for the treatment of wound healing. Significant advancements have been achieved in the past twenty years regarding the understanding of MSCs' molecular mechanisms of action and their potential use in regenerative therapy for a diverse range of diseases, such as autoimmune conditions and inflammatory skin disorders [19]. Recent treatments based on the use of AD-MSCs have been applied in patients to treat various autoimmune and inflammatory skin disorders, such as psoriasis [20], atopic dermatitis [21] and scleroderma [22]; making AD-MSCs a great promise as an alternative approach to regenerative wound treatment.

Another recently explored area of RM are exosomes, which are nano-sized extracellular vesicles (EV) ranging from 30 nm to 200 nm, released by almost all eukaryotic cells. EV serve as mediators for cell-to-cell communication due to their content of unique nucleic acids, proteins, and lipids cargo compositions accordingly to their cell of origin [23]. Although exosomes are considered as a cell-free therapy, culture cell conditions influence on the composition and function of exosomes, emphasizing the importance of maintaining ideal culture conditions during exosome production [24]. Even though exosomes can be collected from a variety of cells, MSC-exosomes have gained great attention due to their immunomodulatory and regenerative properties. Diverse studies have reported their anti-inflammatory [25,26], anti-aging [27] and wound healing effect [28] through their paracrine communication. Interestingly, exosomes have been reported to play a major role in the paracrine effects commonly observed during stem cell therapy [29]. Indeed, MSC-exosomes have been applied as a strategy in a variety of disease models including autoimmune conditions, such as multiple sclerosis [30], type-1 diabetes [31], uveitis [32], rheumatoid arthritis [33], and inflammatory bowel disease [34]. Moreover, their application have also been used in autoimmune related skin conditions, such as atopic dermatitis [35], psoriasis [11] and melanoma [36] with positive outcomes.

In addition, given its low immunogenicity, good biocompatibility and biodegradability, collagen has been recently used as part of the RM area. Collagen, as the most abundant protein found in animals, plays an important structural role by contributing to the molecular architecture, shape, and mechanical properties of tissues

[37]. Studies have reported their application in chronic wounds, burns, venous and diabetic ulcers, within the fields of reconstructive and general surgery, as well as in RM [38]. Novel research has demonstrated no toxicological effect and a remarkable biocompatibility in vivo of the Nile tilapia (*Oreochromis niloticus*) skin graft, which is abundant in type I collagen. These physicochemical properties establish its suitability for a broad range of biomedical applications [39,40]. Interestingly, the extensive cultivation of Nile Tilapia in China produces significant quantities of collagen-rich byproducts during fish processing, which represents a promising potential source of biomedical collagen [37].

Moreover, FGFs are important regulators in the regeneration and repair of damaged tissues, as well as playing an important role in regulating aspects of organogenesis, physiology, and organism development. FGFs potentiate other factors involved during tissue regeneration by delivering information through the synthesis and secretion of signaling molecules into the extracellular space, which activates fibroblast growth factor receptors (FGFRs). The binding of an activated FGFR to an FGF ligand allows for the attachment of numerous signaling proteins (paracrine/endocrine), leading to the potentiation of different specific functions within the cell. Similarly, FGFs have the ability to stimulate fibroblast proliferation and promote angiogenesis, suggesting their potential use in wound healing and facilitating re-epithelization. FGFs stimulate fibroblasts to proliferate and promote angiogenesis, which could potentially be used to heal skin wounds and facilitate re-epithelization. [15,41].

Furthermore, incorporating natural exogenous antioxidants, such as carotenoids, terpenoids, polyphenols, alkaloids, and vitamins, have shown considerable potential to help control wound oxidative stress and thereby accelerate wound healing [42]. A wide range of dietary antioxidants can be consumed to provide enhanced cellular protection; of special interest is Vitamin C (VitC) also known as ascorbic acid, which effectively scavenges reactive oxygen species and regenerates α -tocopherol [43]. VitC plays an important role in coordinating various processes involved in wound healing, as it is an essential cofactor for collagen synthesis and a potent antioxidant. The parenteral administration of VitC has proven to be safe and effective, particularly in critical care scenarios where oral supplementation is insufficient to restore plasma VitC levels. Moreover, the IV (Intravenous) administration of exogenous VitC has been found to inhibit the pro-inflammatory response while promoting anti-inflammatory and wound healing mediators in humans. This approach holds promise as a safe and cost-effective therapeutic method for enhancing tissue repair and expediting the healing process [44].

Case Report

A 73-year-old female patient presented to our Clinic Yolia (Chiapas, Mexico) on August 26, 2021 with an injury in the pretibial region on the lateral right side of her right leg. A small lesion originated on the anterior edge of the tibia and rapidly progressed until the entire circumference of the leg was injured. The patient had a prior diagnosis of venous ulcer, medical history of uncontrolled stage II systemic arterial hypertension, and anemia; which have been previously addressed by cardiology and internal medicine. The patient had been prescribed antimicrobial treatment and systemic steroids without any improvement; therefore, a diagnosis of probable autoimmune lesion secondary to PG was made. Autolytic debridement was performed using hydrogel to promote wound healing and maintain moisture, without any success. Even when a second dressing of hydrocolloid and clobetasol was applied, the patient experienced persistent hypersensitivity, which did not subside with dexamethasone 25 mg, ketorolac 30 mg, tramadol 50 mg, nor pregabalin 75 mg.

On October 11th, 2021, the wound exhibited irregular edges, sloughy tissue, slight odor, abundant exudate, hyperemia, peripheral edema, redness, significant warmth, and severe pain; and null response to opioids nor Non-Steroidal Anti-Inflammatory Drugs (NSAID). Continued treatment with NSAIDs, opioids, and neuromodulators, duloxetine 30 mg were prescribed with no signs of response.

After four months of conventional treatments, which involved promoting moisture (through the use of hydrogels and hydrocolloids), edema control (using systemic and topical prednisone and clobetasol), medication for analgesia and inflammation (Ketorolac, dexamethasone, tramadol, duloxetine, pregabalin, and serratiopeptidase), our medical team decided to explore the field of RM. This novel approach was decided as the patient showed no improvement in wound healing nor in pain management, as depicted in Figure 1a.

On November 18th, 2021 a dosage of 25 million IV AD-MSCs, along with 5 billion IV MSC-exosomes provided by Instituto de Terapia Celular (ITC) were administered in an attempt to control the inflammatory process. After one week, a significant decrease in the inflammatory process and secretions were observed. Additionally, the patient reported an important reduction in pain and edema, as the edges of the wound were not macerated or hyperemic (Figure 1b).

Still, the wound was accentuated by local secretion of metalloproteases after 12 weeks; therefore, a second administration of 25 million IV AD-MSCs and 5 billion IV MSC-exosomes from ITC was performed. Additionally, in order to stimulate tissue regeneration, a tilapia skin graft

obtained from Facultad de Sistema Biologicos e Innovacion Tecnologica by Universidad Autonoma Benito Juarez de Oaxaca was applied directly onto the wound along with topical administration of FGF from ITC (Figure 1c). Similarly, IV vit C (20g) from ITC and iron B-complex oral liposomes supplied by Laboratorio KEMED were used as adjuvants aiming to modulate the inflammatory response at a systemic level. After these regenerative therapies, a clear decrease in the inflammatory process, as well as a reduction in secretions and the edema was observed during the next few weeks. The edges of the wound were neither macerated nor hyperemic, and the patient reported a significant decrease in pain, with a noticeable reduction in exudate. 15 weeks after the tilapia skin graft application, the lesion's extension had ceased by 50%, with very little sloughed tissue remaining.

Three weeks later, a significant improvement was observed as the total healing progress reached approximately 75%, and the patient reported no remaining pain. Nevertheless, edema was still present in the right pelvic limb, specifically in the soleus, the ankle, and the affected leg; which led to an additional topical administration of FGF, displaying overall positive evolution.

At her last follow-up visit, 37 weeks after the first MSC infiltration and 19 weeks after the application of the tilapia skin graft, final blood tests were performed revealing that the sickle cell anemia was in remission. A significant improvement in the wound was notably observed and the patient was discharged from the service with surveillance and outpatient treatment (Figure 1d).

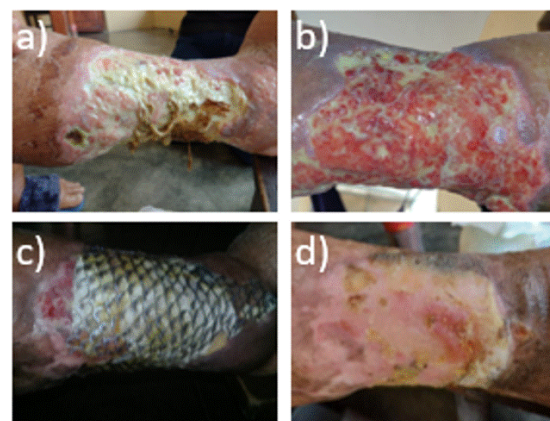


Figure 1: a) PG after conventional treatments failed, b) PG one week after the first application of MSC and MSC-exosomes, c) Tilapia skin application, along with administration of FGF, IV VitC, and iron B-complex oral liposomes, d) 37 weeks after the first application of MSC and MSC-exosomes, the wound has completely healed.

Discussion and Conclusion

To initiate the immunomodulation process at the wound site, an initial approach encompassed the administration

of MSCs and exosomes-MSCs. Given the intricate interplay of dysregulated components characterizing PG, a condition postulated to be primarily T-cell-mediated with a Th17/Th1 profile, and marked by a prevalence of neutrophils in histopathology, the utilization of MSCs and MSC-exosomes was anticipated to yield advantageous outcomes for wound healing. Furthermore, MSCs have demonstrated the capacity to influence the adaptive immune system, particularly T cells, through paracrine secretion. It has been reported that MSCs effectively inhibit the differentiation of Th17 cells by promoting the production of IL-10 and PGE₂, while concurrently suppressing IL-17, IL-22, and IFN- γ [45]. Additionally, the downregulation of overall neutrophil numbers has been reported with MSCs, achieved through the ICAM-1-dependent engulfment of neutrophils [46]. Consequently, the regulatory impact of MSCs was expected to be beneficial in the wound healing process, a notion reinforced by the observations depicted in Figure 1b and consistent with prior research findings.

Another underlying mechanism usually found on the stroma of PG, is the marked presence of Metalloproteinases (MMPs), specifically MMP-9 and to a lesser extent MMP-2. MMPs are typically synthesized by inflammatory cells, including neutrophils, and play a crucial role in breaking down the extracellular matrix to facilitate tissue remodeling and wound repair during trauma. However, the persistent overexpression of MMPs by neutrophils within PG lesions is believed to be responsible for the observed prolonged ulceration [6]. To address tissue loss resulting from the degradation of the extracellular matrix, an innovative approach involving the application of Tilapia skin graft was implemented. Tilapia skin possesses type I collagen, which has been confirmed to exhibit in vivo biocompatibility and finds wide application in the biomedical industries [39]. By implementing this innovative approach, we hypothesize that the reduction of extracellular matrix degradation occurred due to the potential interaction of overexpressed MMPs with the collagen contained within Tilapia skin (Figure 1c) rather than solely degrading the remaining extracellular matrix on autologous tissue.

Additionally, various adjuvants, such as VitC and FGF, were employed to facilitate the complete restoration of tissue function. Wound healing is often accompanied by rapid micronutrient deficiencies, and a notable decrease in VitC levels is commonly observed. This reduction is evident in the increased generation of oxidative free radicals within the wound microenvironment, partly due to the heightened consumption of VitC in various biological processes activated during the repair response (e.g., collagen synthesis) [44]. The IV administration of VitC was believed to address this deficiency. Furthermore, the application of FGF has demonstrated its utility in skin-related diseases. Its direct application, combined with the tilapia skin dressing, provided supplementary support for

wound management, capitalizing on its natural absorption characteristics [15], as the improvements in the healed wound can be observed in Figure 1d.

This case of PG exemplifies the challenges of treating this complex skin condition. Conventional treatments proved to be ineffective in ameliorating the patient's prolonged ulceration, pain, and edema. However, following the implementation of RM therapies, including MSCs, MSC-exosomes, a tilapia skin graft along with FGF, and VitC as adjuvants, positive outcomes were observed within the first week. Throughout the patient's treatment, no significant safety events were identified, affirming the favorable safety profile of MSC therapy. While further research and clinical trials are encouraged to fully comprehend the intricate mechanisms involved, MSCs could emerge as a viable option for managing severe cases of PG and other related ND conditions. The utilization of RM therapies instills hope for patients confronting challenging dermatological conditions, potentially resulting in reduced recovery time and improved overall patient outcomes.

Contributors List

YNOA, PPH and ST have participated in the analyses and draft the manuscript. MRA and SP have made significant contribution with the data and coordination. DE and ST have participated in the design and revision of the manuscript. All authors read and approved the final manuscript.

Acknowledgements

The authors would like to acknowledge the valuable contribution of PhD. Alicia Fonseca from Facultad de Sistemas Biológicos e Innovación Tecnológica, Universidad Autónoma Benito Juárez de Oaxaca FASBIT-UABJO; as well as the contribution of MD. Ricardo Cáceres from Laboratorio KEMED.

Conflicts of Interest

The authors declare not to have any conflict of interest.

Source of Funding

None.

Informed Consent

Written informed consent was obtained from the patient for publication of this manuscript and any accompanying images.

References

1. Ahn C, Negus D, Huang W. Pyoderma gangrenosum: a review of pathogenesis and treatment. *Expert Rev Clin Immunol*. 2018; 14(3): 225-233.
2. Maverakis E, Marzano AV, Le ST, Callen JP, Brügggen MC, Guenova E, et al. Pyoderma gangrenosum. *Nat Rev Dis Primers*. 2020; 6(1): 81.

3. Binus AM, Qureshi AA, Li VW, Winterfield LS. Pyoderma gangrenosum: a retrospective review of patient characteristics, comorbidities and therapy in 103 patients. *Br J Dermatol.* 2011; 165(6): 1244-1250.
4. Ávila-López VH, Navarrete-Solis J, Hernández-Martínez SJ. Pioderma Gangrenoso: Características clínicas, histopatológicas y revisión de la literatura en pacientes de una unidad de tercer nivel del Noreste de México. *Dermatol Rev Mex.* 2021; 65(2): 149-158.
5. Wang EA, Steel A, Luxardi G, Mitra A, Patel F, Cheng MY, et al. Classic Ulcerative Pyoderma Gangrenosum Is a T Cell-Mediated Disease Targeting Follicular Adnexal Structures: A Hypothesis Based on Molecular and Clinicopathologic Studies. *Front Immunol.* 2018; 8: 1980.
6. Flora A, Kozera E, Frew JW. Pyoderma gangrenosum: A systematic review of the molecular characteristics of disease. *Exp Dermatol.* 2022; 31(4): 498-515.
7. Antiga E, Maglie R, Volpi W, Bianchi B, Berti E, Marzano AV, et al. T helper type 1-related molecules as well as interleukin-15 are hyperexpressed in the skin lesions of patients with pyoderma gangrenosum. *Clin Exp Immunol.* 2017; 189(3): 383-391.
8. Ortega-Loayza AG, Friedman MA, Reese AM, Liu Y, Greiling TM, Cassidy PB, et al. Molecular and Cellular Characterization of Pyoderma Gangrenosum: Implications for the Use of Gene Expression. *J Invest Dermatol.* 2022; 142(4): 1217.e14 -1220.e14.
9. Ye MJ, Ye JM. Pyoderma gangrenosum: a review of clinical features and outcomes of 23 cases requiring inpatient management. *Dermatol Res Pract.* 2014; 2014: 461467.
10. Zhang Y, Bai X, Shen K, Luo L, Zhao M, Xu C, et al. Exosomes Derived from Adipose Mesenchymal Stem Cells Promote Diabetic Chronic Wound Healing through SIRT3/SOD2. *Cells.* 2022; 11(16): 2568.
11. Zhang Y, Yan J, Li Z, Zheng J, Sun Q. Exosomes Derived from Human Umbilical Cord Mesenchymal Stem Cells Alleviate Psoriasis-like Skin Inflammation. *J Interferon Cytokine Res.* 2022; 42(1): 8-18.
12. Monavarian M, Kader S, Moeinzadeh S, Jabbari E. Regenerative Scar-Free Skin Wound Healing. *Tissue Eng Part B Rev.* 2019; 25(4): 294-311.
13. Comino-Sanz IM, López-Franco MD, Castro B, Pancorbo-Hidalgo PL. The Role of Antioxidants on Wound Healing: A Review of the Current Evidence. *J Clin Med.* 2021; 10(16): 3558.
14. Bian D, Wu Y, Song G, Azizi R, Zamani A. The application of mesenchymal stromal cells (MSCs) and their derivative exosome in skin wound healing: a comprehensive review. *Stem Cell Res Ther.* 2022; 13(1): 24.
15. Okikiade A, Osharode A, Oloye-Afolayan O, Ogunesan D, Adijat O, Chibuike KU, et al. A Review of the Therapeutic Potentials of Stem Cells, Fibroblast Growth Factors and T-cells in Regenerative Medicine. *Advances in Research.* 2022; 23(6): 38-66.
16. Nourian Dehkordi A, Mirahmadi Babaheydari F, Chehelgerdi M, Raeisi Dehkordi S. Skin tissue engineering: wound healing based on stem-cell-based therapeutic strategies. *Stem Cell Res Ther.* 2019; 10(1): 111.
17. Kocan B, Maziarz A, Tabarkiewicz J, Ochiya T, Banaś-Ząbczyk A. Trophic Activity and Phenotype of Adipose Tissue-Derived Mesenchymal Stem Cells as a Background of Their Regenerative Potential. *Stem Cells Int.* 2017; 2017: 1653254.
18. Son WC, Yun JW, Kim BH. Adipose-derived mesenchymal stem cells reduce MMP-1 expression in UV-irradiated human dermal fibroblasts: therapeutic potential in skin wrinkling. *Biosci Biotechnol Biochem.* 2015; 79(6): 919-925.
19. Li Y, Ye Z, Yang W, Zhang Q, Zeng J. An Update on the Potential of Mesenchymal Stem Cell Therapy for Cutaneous Diseases. *Stem Cells Int.* 2021; 2021: 8834590.
20. Comella K, Parlo M, Daly R, Dominessy K. First-in-man intravenous implantation of stromal vascular fraction in psoriasis: a case study. *Int Med Case Rep J.* 2018; 11: 59-64.
21. Kim M, Lee SH, Kim Y, Kwon Y, Park Y, Lee HK, et al. Human Adipose Tissue-Derived Mesenchymal Stem Cells Attenuate Atopic Dermatitis by Regulating the Expression of MIP-2, miR-122a-SOCS1 Axis, and Th1/Th2 Responses. *Front Pharmacol.* 2018; 9: 1175.
22. Park Y, Lee YJ, Koh JH, Lee J, Min HK, Kim MY, et al. Clinical Efficacy and Safety of Injection of Stromal Vascular Fraction Derived from Autologous Adipose Tissues in Systemic Sclerosis Patients with Hand Disability: A Proof-Of-Concept Trial. *J Clin Med.* 2020; 9(9): 3023.
23. Wu P, Zhang B, Ocansey DKW, Xu W, Qian H. Extracellular vesicles: A bright star of nanomedicine. *Biomaterials.* 2021; 269: 120467.
24. Colao IL, Corteling R, Bracewell D, Wall I. Manufacturing Exosomes: A Promising Therapeutic Platform. *Trends Mol Med.* 2018; 24(3): 242-256.
25. Xia C, Zeng Z, Fang B, Tao M, Gu C, Zheng L, et al. Mesenchymal stem cell-derived exosomes ameliorate intervertebral disc degeneration via anti-oxidant and anti-inflammatory effects. *Free Radic Biol Med.* 2019; 143: 1-15.
26. Yang C, Lim W, Park J, Park S, You S, Song G. Anti-inflammatory effects of mesenchymal stem cell-derived exosomal microRNA-146a-5p and microRNA-548e-5p on human trophoblast cells. *Mol Hum Reprod.* 2019; 25(11): 755-771.
27. Zhang K, Yu L, Li FR, Li X, Wang Z, Zou X, et al. Topical Application of Exosomes Derived from Human Umbilical Cord Mesenchymal Stem Cells in Combination with Sponge Spicules for Treatment of Photoaging. *Int J Nanomedicine.* 2020; 15: 2859-2872.
28. Hu Y, Tao R, Chen L, Xiong Y, Xue H, Hu L, et al. Exosomes derived from pioglitazone-pretreated MSCs accelerate diabetic wound healing through enhancing angiogenesis. *J Nanobiotechnology.* 2021; 19(1): 150.
29. Ha DH, Kim HK, Lee J, Kwon HH, Park GH, Yang SH, et al. Mesenchymal Stem/Stromal Cell-Derived Exosomes for Immunomodulatory Therapeutics and Skin Regeneration. *Cells.* 2020; 9(5): 1157.
30. Li Z, Liu F, He X, Yang X, Shan F, Feng J. Exosomes derived from mesenchymal stem cells attenuate inflammation and demyelination of the central nervous system in EAE rats by regulating the polarization of microglia. *Int Immunopharmacol.* 2019; 67: 268-280.
31. Nojehdehi S, Soudi S, Hesampour A, Rasouli S, Soleimani M, Hashemi SM. Immunomodulatory effects of mesenchymal stem cell-derived exosomes on experimental type-1 autoimmune diabetes. *J Cell Biochem.* 2018; 119(11): 9433-9443.
32. Bai L, Shao H, Wang H, Zhang Z, Su C, Dong L, et al. Effects of Mesenchymal Stem Cell-Derived Exosomes on Experimental Autoimmune Uveitis. *Sci Rep.* 2017; 7(1): 4323.
33. Chen Z, Wang H, Xia Y, Yan F, Lu Y. Therapeutic Potential of Mesenchymal Cell-Derived miRNA-150-5p-Expressing Exosomes in Rheumatoid Arthritis Mediated by the Modulation of MMP14 and VEGF. *J Immunol.* 2018; 201(8): 2472-2482.
34. Mao F, Wu Y, Tang X, Kang J, Zhang B, Yan Y, et al. Exosomes Derived from Human Umbilical Cord Mesenchymal Stem Cells Relieve Inflammatory Bowel Disease in Mice. *Biomed Res Int.* 2017; 2017: 5356760.

35. Cho BS, Kim JO, Ha DH, Yi YW. Exosomes derived from human adipose tissue-derived mesenchymal stem cells alleviate atopic dermatitis. *Stem Cell Res Ther*. 2018; 9(1): 187.
36. Shamili FH, Bayegi HR, Salmasi Z, Sadri K, Mahmoudi M, Kalantari M, et al. Exosomes derived from TRAIL-engineered mesenchymal stem cells with effective anti-tumor activity in a mouse melanoma model. *Int J Pharm*. 2018; 549(1-2): 218-229.
37. Ge B, Wang H, Li J, Liu H, Yin Y, Zhang N, et al. Comprehensive Assessment of Nile Tilapia Skin (*Oreochromis niloticus*) Collagen Hydrogels for Wound Dressings. *Mar Drugs*. 2020; 18(4): 178.
38. Shekhter AB, Fayzullin AL, Vukolova MN, Rudenko TG, Osipychcheva VD, Litvitsky PF. Medical Applications of Collagen and Collagen-Based Materials. *Curr Med Chem*. 2019; 26(3): 506-516.
39. Zhang J, Jeevithan E, Bao B, Wang S, Gao K, Zhang C, et al. Structural characterization, in-vivo acute systemic toxicity assessment and in-vitro intestinal absorption properties of tilapia (*Oreochromis niloticus*) skin acid and pepsin solubilized type I collagen. *Process Biochemistry*. 2016; 51(12): 2017-2025.
40. Song WK, Liu D, Sun LL, Li BF, Hou H. Physicochemical and Biocompatibility Properties of Type I Collagen from the Skin of Nile Tilapia (*Oreochromis niloticus*) for Biomedical Applications. *Mar Drugs*. 2019; 17(3): 137.
41. Maddaluno L, Urwyler C, Werner S. Fibroblast growth factors: key players in regeneration and tissue repair. *Development*. 2017; 144(22): 4047-4060.
42. Barku VYA. Wound Healing: Contributions from Plant Secondary Metabolite Antioxidants. In Dogan KH (Ed.), *Wound Healing-Current Perspectives*. Rijeka, Croatia: Intech Open. 2019. pp. 13.
43. Williamson J, Hughes CM, Davison GW. Exogenous Plant-Based Nutraceutical Supplementation and Peripheral Cell Mononuclear DNA Damage Following High Intensity Exercise. *Antioxidants (Basel)*. 2018; 7(5): 70.
44. Mohammed BM, Fisher BJ, Kraskauskas D, Ward S, Wayne JS, Brophy DF, et al. Vitamin C promotes wound healing through novel pleiotropic mechanisms. *Int Wound J*. 2016; 13(4): 572-584.
45. Song N, Scholtemeijer M, Shah K. Mesenchymal Stem Cell Immunomodulation: Mechanisms and Therapeutic Potential. *Trends Pharmacol Sci*. 2020; 41(9): 653-664.
46. Jiang D, Muschhammer J, Qi Y, Kügler A, de Vries JC, Saffarzadeh M, et al. Suppression of Neutrophil-Mediated Tissue Damage-A Novel Skill of Mesenchymal Stem Cells. *Stem Cells*. 2016; 34(9): 2393-2406.