

## Pulmonary Embolism Associated With Thrombi of the Right Heart: What Appropriate Care? Clinical Case and Literature Review

### Research Article

**Taryètba A. Arthur Seghda<sup>1\*</sup>, Miguel A.M Lopez<sup>1</sup>, Théodore Boro<sup>2</sup>, Issa Sawadogo<sup>1</sup>, Aminata Niakara<sup>3</sup>, Saidou Dimzouré<sup>1</sup>, Georges R.C Millogo<sup>4</sup>, Nobila V Yaméogo<sup>4</sup>, Elodie Sib<sup>5</sup>, André Samadoulougou<sup>1</sup> and Patrice Zabsonré<sup>4</sup>**

<sup>1</sup>Cardiology department, Bogodogo University Hospital, Ouagadougou, Burkina Faso

<sup>2</sup>Cardiology department, Saint Camille Hospital, Ouagadougou, Burkina Faso

<sup>3</sup>Cardiology department Workers' Health Office, Ouagadougou Burkina Faso

<sup>4</sup>Cardiology department, Yalgado Ouédraogo University Hospital, Ouagadougou, Burkina Faso

<sup>5</sup>Cardiology department, International Polyclinic of Ouagadougou, Burkina Faso

**Received:** June 23, 2020; **Accepted:** July 06, 2020; **Published:** July 07, 2020

**\*Corresponding author:** Taryètba André Arthur Seghda, Cardiology department, Bogodogo University Hospital, Ouagadougou, Burkina Faso

**Copyright:** © 2020 Taryètba André Arthur Seghda. This is an open-access article distributed under the terms of the Creative Commons Attribution License, which permits unrestricted use, distribution, and reproduction in any medium, provided the original author and source are credited.

### Abstract

Pulmonary embolism associated with right heart thrombi mainly in the atrium, raise therapeutic dilemmas. Their relative rarity does not allow the development of a consensus recommendation for standardized treatment. We set out to describe a typical clinical case of a pulmonary embolism with large floating thrombus of the right atrium and to do a literature review in order to present a summary of the practices and results obtained by several authors. It appears that three types of treatment can be used. Thrombolysis turns out to be the treatment most often used even in patients whose hemodynamic state is stable.

### Key words

pulmonary embolism, right heart thrombi, management.

### Introduction

The management of pulmonary embolism associated with right heart thrombi has not yet been unanimously accepted by authors and learned societies [1]. This lack of consensus could be explained by the relative rarity of this clinical form of pulmonary embolism. Its gravity, however, requires rapid, adequate care and should leave no room for hesitation, much less expectation. This is especially true for type A thrombi in which echocardiography reveals a serpentine mobile mass of the right atrium [2]. Indeed, in this ultrasound type, in the absence of treatment, the

mortality would reach 100% [3]. The therapeutic options found in the literature fall under three sometimes inclusive orders which are heparinotherapy, interventional or surgical embolectomy and thrombolysis. In the absence of established therapeutic guidelines, the decision on the therapeutic option is left to the practitioner's clinical judgment.

The objective of this work is to report our experience of the management of pulmonary embolism associated with right intracardiac thrombi through an observation and to

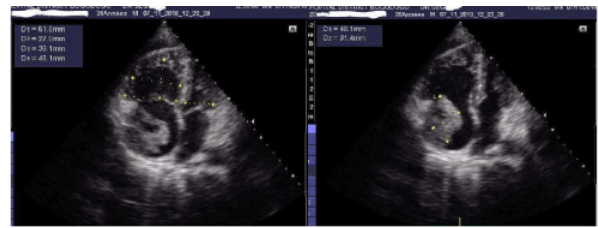
make a literature review to identify what should be done in the light of the results obtained by other authors around the world.

**Methodology**

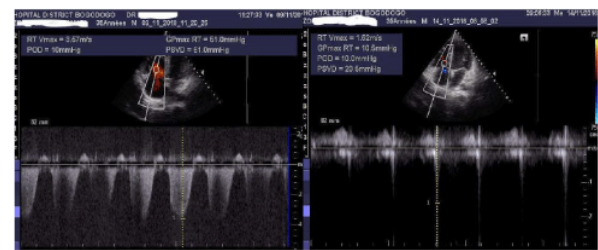
This is a review of scientific articles dealing with pulmonary embolism that have similar characteristics to a clinical observation from our cardiology department. We have looked at PubMed publications over the past ten years using the Mesh terms “pulmonary embolism”, “right heart thrombi” and “management”. A reading of the summaries allowed us to exclude articles not dealing with the issue. Ont été exclus de l'étude les revues scientifiques, les recommandations, les mises au point, les articles traitant d'embolie pulmonaire avec thrombi du Coeur droits chez des femmes enceintes ou chez dans des néoplasies et celles secondaires à des cathéter veineux centraux. The complete analysis of the articles selected consisted of a description of the location of the thrombi, their mobility, the treatments received and the mortality. The hemodynamic state of the patients will be considered stable in the absence of signs of shock or collapse.

**Observation and Results**

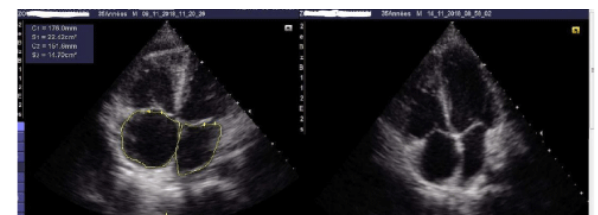
We report the clinical observation of a 35-year-old patient admitted for severe acute chest pain with acute dyspnea. In his history we find abdominal pain 2 months ago whose investigations, limited in general medicine were not conclusive. The interrogation found a notion of syncope with minimal trauma to the face and a hemoptoic cough a week earlier. This symptomatology was preceded by acute dyspnea and chest pain. The general examination found an anxious and agitated patient, a blood pressure at 110/70 mmHg, a heart rate at 110 beats per min. Its peripheral ambient air saturation was 80% improved by 8 liters of oxygen per minute to 95%. The physical cardiovascular examination found a stable hemodynamic state and signs of right ventricular failure. Examination of the lower limbs found no signs of venous thrombosis. The electrocardiogram was part of a regular sinus tachycardia at 120 cycles per minute with a vertical axis, an S1Q3T3 aspect and almost circumferential negative T waves. A front chest X-ray taken before admission found minimal dilation of the right ventricle (RV), right atrium (RA) and the trunk of the pulmonary artery. On cardiac ultrasound we found dilated right cavities with a OD seat of a voluminous serpentine mass, hypermobile prolapsing in RV and whose echostructure was compatible with a thrombus (Figure



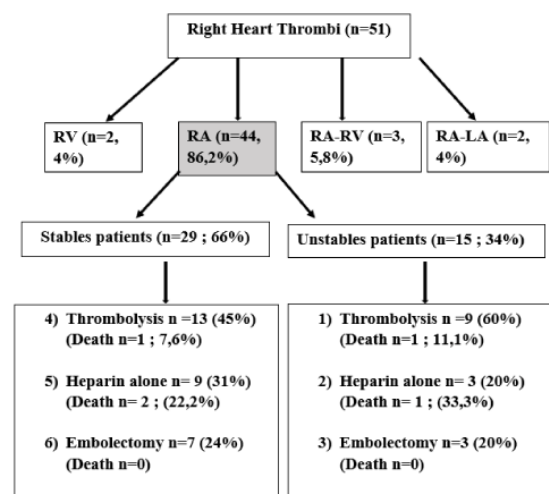
**Figure 1:** Large thrombus in dilated right atrium, snaking, and prolabant in dilated RV



**Figure 2:** Severe pulmonary hypertension (2a) normalized after thrombolysis (2b).



**Figure 3:** Complete disappearance of the thrombus after thrombolysis (3a) and normalization of right heart cavities size (3b)



**Figure 4:** Description, management and mortality in 51 pulmonary embolism associated with right heart thrombi

**Table 1:** Therapeutic options for the management of pulmonary embolism associated with right heart thrombi in 36 publications

Study	Hemodynamicstatus	Thrombi location	Management				Number of patients	Death
			Thrombolysis	Embolectomy		Heparinalone		
				Chirurgical	Instrumental			
Seghda et al. (2018)	S (3) U(3)	RA	+				6	1
Seghda et al. (2018)	S (2) U(3)	RA				+	5	4
Galéano et al. (2018)	S	RA		+			4	0
Zafar et al. (2018)	S	RA				+	1	0
Salsano et al. (2017)	S	RA	+				1	0
Hussein et al. (2017)	S	RA				+	1	0
Ellensen et al. (2017)	S	RA LA		+			1	0
Habibi et al. (2017)	S	RA		+			1	0
Portugues et al. (2017)	S	RA				+	1	0
Abbasi et al. (2016)	U	RA	+				1	0
Singh et al. (2016)	U	RA		+			1	0
Shokr et al. (2016)	S	RA	+				1	0
Lanza et al. (2016)	S	RA		+			1	0
Narrang et al. (2016)	U	RA	+		+		1	0
Brault et al. (2015)	U	RA	+				1	0
Pampin Huerta et al. (2016)	S	RA	+				1	0
Nkoke et al. (2015)	S	RA	+				1	0
Kenny et al. (2015)	U	RA	+				1	0
Martirez et al. (2015)	S	RA	+				1	0
Othman et al. (2016)	S	RA	+				1	0
Agarwal et al. (2014)	U	RA RV	+				1	0
Garala et al. (2013)	S	RA RV				+	1	0
Sharma et al. (2012)	S	RA	+				1	0
Hisatomi et al. (2013)	U	RA		+			1	0
Shin et al (2013)	S	RA				+	1	0
Pellegrini et al. (2012)	S	RA	+				1	0
CordeiroPicccara et al. (2012)	S	RA		+			1	0
Debney et al. (2012)	U	RA	+				1	0
Turfan et al. (2012)	U	RA	+				1	0
Panduranga et al. (2010)	S	RA				+	1	0
Louali et al. (2010)	S	1 RA 2 RV				+	3	0
Hajj Chahine et al. (2010)	U	RA		+			1	0
Hewing et al. (2010)	U	RA RV	+				1	0
Burns et al. (2009)	S	RA	+				1	0
Ram et al. (2009)	S	RA				+	1	0
Turgut et al. (2010)	S	RA LA				+	1	0
Stanziola et al. (2012)	S	RA	+				1	0

**Citation:** Seghda TAA, Lopez MAM, Boro T, Sawadogo I, Niakara A, Dimzouré S, et al. Pulmonary Embolism Associated With Thrombi of the Right Heart: What Appropriate Care? Clinical Case and Literature Review. ES J Cardiol. 2020; 1(3): 1017.0; 1(3): 1016.

1a and 1b). The systolic function of the RV was altered with a systolic excursion of the plane of the tricuspid ring at 7 mm and pulmonary pressures at 61 mmHg (Figure 2a). In the absence of contraindications to fibrinolysis, the therapeutic management consisted of an infusion of 1.5 million international units of streptokinase over 2 hours, oxygenation at 8 liters / minute in the mask then a curative heparin therapy. The evolution was marked by an improvement in the respiratory state with progressive reduction of oxygen therapy, a complete disappearance of the pain. An echocardiographic control immediately at the end of thrombolysis always finds the thrombus in the RA which disappears completely 48 hours later 5 (Figure 3) with normalization of the systolic function of the RV, the size of the right cavities at 5 days (Figure 3b), pulmonary pressures (Figure 2b). There had been no complications from thrombolysis. The initial etiological assessment was normal. The patient being followed in the department will benefit from a thrombophilia assessment at the end of the antivitamin K treatment.

Through the literature review, we found 104 articles dealing with the subject. From an analysis of the summaries, we selected 41 articles, including 4 reviews [4–43]. Des spécificités propres à certains terrains peuvent influencer la décision thérapeutique notamment la présence d'un cancer avancé, d'une grossesse ou ponction vasculaire récente. Cette considération a conduit à l'exclusion de notre travail de ces patients. Apart from journals, all publications are series ranging from 1 to 11 patients included according to the authors for a total of 51 patients. Table 1 reports all the studies found and presents a distribution described in Figure I, according to the location of the thrombi, the hemodynamic state of the patients, the treatment and the mortality. The atrium was the most frequent localization of right intracavitary thrombi (86.2%) with a proportion of stable patients of 66% versus 34% for unstable patients. Whether a stable patient or not, thrombolysis remained the most often used therapeutic option by the authors, with higher proportions in the unstable group (60%) compared to the stable (45%). Mortality in any hemodynamic state was higher in patients who received heparin only compared to those treated with thrombolysis and embolectomy. Surgical embolectomy was the therapeutic option in certain particular forms, in particular with fixed intra-atrial thrombus that was not very mobile [16] or embedded in a permeable foramen with paradoxical embolism [12].

## Discussion

The actual prevalence of pulmonary embolism associated with right intracavitary thrombi is not known. Values around 4% are reported in large registers [2,35]. Most of the studies found in the literature are series of cases. This makes it difficult to make recommendations based on solid evidence. However, the recommendations of the European Cardiology Society are more or less clear on the potential severity of this clinical form [1].

The characteristics of the intracavitary thrombus influence the embolic risk. They will determine the practitioner's therapeutic option and also the prognosis. A large, serpentine, hypermobile, pedunculated thrombus in the right atrium imposes a higher embolic risk on the patient. The assessment of the probability of early death in these cases should not be limited to existing conventional scores. Our clinical case summarizes the complexity of adapted treatment by raising a question that many practitioners are confronted with. What should be the management of a pulmonary embolism with thrombus of the right heart, in particular of the atrium, mobile in a patient whose hemodynamic state judged by blood pressure and the absence of sign of shock is stable? From a diagnostic point of view, we opted not to take any risk in mobilizing the patient to confirm the pulmonary embolism with a chest CT scan. Indeed, the diagnosis of embolism should be retained on indirect signs which are the presence, of a pulmonary hypertension, a dilation of the right cavities, an alteration of the RV systolic function and thrombus. From the therapeutic point of view, we decided to have a thrombolysis. This option carries the risk of fragmentation of the thrombus with distal embolization. However, it remains the best according to studies carried out with a larger population [7].

The risk of embolization is great when the thrombus is large and mobile. Thrombolysis could also precipitate this phenomenon. However, it is better for the patient to embolize on a distal artery with a small thrombus than to obstruct the trunk of the pulmonary artery or a large branch with a large thrombus. Thrombolysis not only reduces pulmonary pressures but also reduces the size of the thrombus.

Embolectomy seems to be the most reassuring treatment option due to the absence of recorded deaths. This should however be qualified due to the small number of patients who benefit from this procedure. It requires a

suitable technical platform and, above all, hemodynamic stability for the patient. This perhaps explains the fact that practitioners most often resort to thrombolysis because it is more accessible and faster to put in place.

In his review of 328 patients with pulmonary embolism with right intracavitary thrombi from 1992 to 2013, Athappan et al. found a lower mortality in the groups treated by thrombolysis and embolectomy with respectively 13.7% and 18.3% while that of heparin therapy alone was 37.1% [7]. Our review is comparable to that of Athappan.

Divergent results are found in the literature. Thus Akilli et al. observed in a retrospective study of 29 patients, 100% mortality in patients who had undergone a surgical embolectomy against 18% and 27% respectively for thrombolysis and heparin therapy [6]. This observation deserves a critical analysis taking into account the conditions of patients referred for surgery. On the other hand, the surgical option is more efficient when the teams are more trained and the surgery earlier [13,45].

## Conclusion

The right atrium is the most common location of thrombi in pulmonary embolism. Echocardiography is the essential tool for diagnosis and management. It allows you to appreciate the characteristics of the thrombus, which is the basis of the treatment decision. In the presence of a floating RA thrombus, thrombolysis is the most appropriate treatment regardless of the patient's hemodynamic state.

## References

- Konstantinides SV, Meyer G, Becattini C, Bueno H, Geersing G-J, Harjola V-P, et al. 2019 ESC Guidelines for the diagnosis and management of acute pulmonary embolism developed in collaboration with the European Respiratory Society (ERS) The Task Force for the diagnosis and management of acute pulmonary embolism of the European Society of Cardiology (ESC). *Eur Heart J*. 21 janv 2020;41(4):543-603
- Echocardiography TEWGO, Kronik G. The European Cooperative Study on the clinical significance of right heart thrombi. *Eur Heart J*. 1989 Dec 1;10(12):1046-59.
- Rose PS, Punjabi NM, Pearse DB. Treatment of right heart thromboemboli. *Chest*. 2002 Mar;121(3):806-14.
- Abbasi OZ, Doan TT, Duggal S, Nair SU, Quinn SM. Utilization of bedside ultrasound in the diagnosis and management of massive pulmonary embolism: a case report. *Radiol Case Rep*. 2016 Dec;11(4):447-9.
- Agarwal V, Nalluri N, Shariff MA, Akhtar MS, Olkovsky Y, Kitsis PE, et al. Large embolus in transit - an unresolved therapeutic dilemma (case report and review of literature). *Heart Lung J Crit Care*. 2014 Apr;43(2):152-4.
- Akilli H, Gül EE, Arıbaşı A, Özdemir K, Kayrak M, Erdoğan HI. Management of right heart thrombi associated with acute pulmonary embolism: a retrospective, single-center experience. *Anadolu Kardiyol Derg AKD Anatol J Cardiol*. 2013 Sep;13(6):528-33.
- Athappan G, Sengodan P, Chacko P, Gandhi S. Comparative efficacy of different modalities for treatment of right heart thrombi in transit: a pooled analysis. *Vasc Med Lond Engl*. 2015 Apr;20(2):131-8.
- Brault-Meslin O, Mazouz S, Nallet O, Cattan S, Amara W. [Free floating thrombus in right cardiac chambers and thrombolysis]. *Ann Cardiol Angeiol (Paris)*. 2015 Nov;64(5):410-3.
- Burns KEA, McLaren A. Catheter-related right atrial thrombus and pulmonary embolism: a case report and systematic review of the literature. *Can Respir J*. 2009 Oct;16(5):163-5.
- Cordeiro Piçarra B, Santos AR, Dionísio P, Vasconcelos J, Banazol N, Lourenço S, et al. Right atrial thrombus: a rare presentation of plasminogen activator inhibitor deficiency. *Rev Port Cardiol Orgao Of Soc Port Cardiol Port J Cardiol Off J Port Soc Cardiol*. 2012 Feb;31(2):171-4.
- Debney MT. Acute pulmonary embolus with visible right heart thrombus in transit. *Emerg Med J EMJ*. 2012 Jan;29(1):72-3.
- Ellensen VS, Saeed S, Geisner T, Haaverstad R. Management of thromboembolism-in-transit with pulmonary embolism. *Echo Res Pract*. 2017;4(4):K47-K51.
- Fukuda I, Taniguchi S, Fukui K, Minakawa M, Daitoku K, Suzuki Y. Improved outcome of surgical pulmonary embolectomy by aggressive intervention for critically ill patients. *Ann Thorac Surg*. 2011 Mar;91(3):728-32.
- Galeano-Valle F, Demelo-Rodríguez P, García-Fernández-Bravo I, Rodríguez-Abella H, Irabien-Ortiz Á, Fortuny-Ribas R, et al. Early surgical treatment in patients with pulmonary embolism and thrombus-in-transit. *J Thorac Dis*. 2018 Apr;10(4):2338-45.
- Garala K, Chelliah R, Hudson I. Massive pulmonary embolus and a precariously positioned thrombus: teetering on a knife edge! *BMJ Case Rep*. 2013 Jun 24;2013.
- Habibi R, Altamirano AJ, Dadkhal S. Clot in Lung, Clot in Heart: A Case Report of Tumor-Like Thrombus in Right Atrium. *Clin Med Insights Case Rep*. 2017;10:1179547617698460.
- Hajj-Chahine J, Jayle C, Tomasi J, Corbi P. Successful surgical management of massive pulmonary embolism during the second trimester in a parturient with heparin-induced thrombocytopenia. *Interact Cardiovasc Thorac Surg*. 2010 Nov;11(5):679-81.
- Hewing B, Ghaeni L, Dreger H, Fallenberg EM, Panda A, Baumann G, et al. Echocardiographic diagnosis, management and monitoring of pulmonary embolism with right heart thrombus in a patient with myotonic dystrophy: a case report. *Cardiovasc Ultrasound*. 2010 May 16;8:18.
- Hisatomi K, Yamada T, Onohara D. Surgical embolectomy of a floating right heart thrombus and acute massive pulmonary embolism: report of a case. *Ann Thorac Cardiovasc Surg Off J Assoc Thorac Cardiovasc Surg Asia*. 2013;19(4):316-9.
- Hussain B, Tipoo Sultan FA, Shahzad T, Punjani S. Caught in the act - Migration of a large right atrial thrombus to pulmonary artery during transthoracic echocardiography - A case report. *JPMA J Pak Med Assoc*. 2017 Dec;67(12):1927-9.
- Kenny JF, Zhong X, Brown C, Das D, Royall B, Kapoor M. Bedside echocardiography for undifferentiated hypotension: diagnosis of a right heart thrombus. *West J Emerg Med*. 2015 Jan;16(1):178-80.
- Lanza D, Paolini R, Rodella E, Danesi TH, Cresce G, Salvador L, et al. [Central venous catheter-related right atrial thrombosis in a patient with Hodgkin's lymphoma]. *G Ital Cardiol* 2006. 2016 May;17(5):388-90.

23. Louali FE, Tamdy A, Soufiani A, Oukerraj L, Omari D, Bounjoum F, et al. Cardiac thrombosis as a manifestation of Behçet syndrome. *Tex Heart Inst J*. 2010;37(5):568-71.
24. Martires JS, Stein SJ, Kamangar N. Right heart thrombus in transit diagnosed by bedside ultrasound. *J Emerg Med*. 2015 Apr;48(4):e105-108.
25. Mohan B, Chhabra ST, Gulati A, Mohan Mittal C, Mohan G, Tandon R, et al. Clinical and echocardiographic diagnosis, follow up and management of right-sided cardiac thrombi. *Indian Heart J*. 2013 Oct;65(5):529-35.
26. Narang A, Mediratta A, Estrada JR, Rosenberg J, DeCara JM, Howell MD, et al. Transcatheter Therapy for a Large Mobile Right Atrial Thrombus and Massive Pulmonary Embolism. *J Invasive Cardiol*. 2016 May;28(5):E49-51.
27. Nkoke C, Faucher O, Camus L, Flork L. Free Floating Right Heart Thrombus Associated with Acute Pulmonary Embolism: An Unsettled Therapeutic Difficulty. *Case Rep Cardiol*. 2015;2015:364780.
28. Othman M, Briasoulis A, Afonso L. Thrombolysis for Right Atrial Thrombus-in-Transit in a Patient With Massive Pulmonary Embolism. *Am J Ther*. 2016 Jun;23(3):e930-932.
29. Pampín-Huerta FR, Moreira-Gómez D, Lozano-Requelme ML, Molina-Nieto F, Fontán-García-Boente L, Moreira-Pacheco M. Cardiac arrest during a twin birth caesarean delivery. *Rev Esp Anestesiol Reanim*. 2016 Apr;63(4):235-9.
30. Panduranga P, Mukhaini M, Saleem M, Al-Delamie T, Zachariah S, Al-Taie S. Mobile right heart thrombus with pulmonary embolism in a patient with polycythemia rubra vera and splanchnic vein thrombosis. *Heart Views Off J Gulf Heart Assoc*. 2010 Mar;11(1):16-20.
31. Pellegrini L, Le Dolley Y, Marot B, Riberi A, Bellezza M, Kerbaul F. [Interest of echocardiography in the diagnosis and monitoring of a pulmonary embolism complicating a free-floating thrombus in right heart cavities]. *Ann Fr Anesth Reanim*. 2012 Mar;31(3):246-50.
32. Português J, Calvo L, Oliveira M, Pereira VH, Guardado J, Lourenço MR, et al. Pulmonary Embolism and Intracardiac Type A Thrombus with an Unexpected Outcome. *Case Rep Cardiol*. 2017;2017:9092576.
33. Ram R, Swarnalatha G, Rakesh Y, Jyostna M, Prasad N, Dakshinamurthy KV. Right atrial thrombus due to internal jugular vein catheter. *Hemodial Int Int Symp Home Hemodial*. 2009 Jul;13(3):261-5.
34. Salsano A, Sportelli E, Olivieri GM, Di Lorenzo N, Borile S, Santini F. RVAD Support in the Setting of Submassive Pulmonary Embolism. *J Extra Corpor Technol*. 2017;49(4):304-6.
35. Seghda TAA, Yaméogo NV, Millogo GRC, Kagambega L, Kologo J, Boro T, et al. Prise en charge et pronostic des embolies pulmonaires associées à des thrombi intracavitaires droits : à propos d'une série prospective au centre Hospitalier Universitaire Yalgado Ouédraogo. *Annales de Cardiologie et d'Angéiologie*. 1 avr 2019;68(2):65-70.
36. Sharma A, Udgire PP, Khan S, Goyal BK, Gautam S. Pulmonary thromboembolism and right heart thromboemboli--an experience with tenecteplase. *J Assoc Physicians India*. 2012 Oct;60:52-4.
37. Shin J, Kim G, Kil H, Chang M. Successful use of low molecular weight heparin in intracardiac thrombus of an extremely low birth weight infant. *Indian J Pediatr*. 2013 Sep;80(9):779-80.
38. Shokr M, Kaur R, Belgrave K, Javed A, Elder M, Cardozo S, et al. Ultrasound Assisted Catheter Directed Thrombolysis in the Management of a Right Atrial Thrombus: A New Weapon in the Armamentarium? *Case Rep Cardiol*. 2016;2016:4167397.
39. Singh A, Mehta Y, Parakh R, Kohli V, Trehan N. Role of hybrid operating room in surgery for the right atrial thrombus, pulmonary thrombi, and ventricular septal rupture after myocardial infarction. *Ann Card Anaesth*. 2016 Dec;19(4):717-21.
40. Stanziola AA, Padula S, Carpentieri E, Rea G, Maniscalco M, Sofia M. Right heart and pulmonary thromboembolism from extensive splanchnic vein thrombosis after splenectomy for myeloproliferative disease. *Heart Lung J Crit Care*. 2012 Apr;41(2):188-91.
41. Turfan M, Vatankulu MA, Murat SN, Oksuz F, Duran M, Ornek E. Thrombolytic treatment of simultaneous pulmonary embolism and impending paradoxical embolism through a patent foramen ovale: a different thrombolytic regimen. *Heart Lung Circ*. 2012 Apr;21(4):225-8.
42. Turgut O, Yalta K, Yilmaz MB, Dizman R, Tandogan I. Free-floating biatrial thrombi with concomitant saddle pulmonary embolism. *Int J Cardiol*. 2010 Sep 24;144(1):e11-13.
43. Zafar H, Anderson L, Cox AT, Bastiaenen R. Pulmonary embolism and infarction with a paradoxical thrombus visualised in both atria. *BMJ Case Rep*. 2018 May 30;2018.
44. Fukuda I, Taniguchi S, Fukuda W. Management of right heart thrombi associated with acute pulmonary embolism: is there no room for surgical embolectomy? *Anadolu Kardiyol Derg AKD Anatol J Cardiol*. 2013 Sep;13(6):534-5.
45. Leacche M, Unic D, Goldhaber SZ, Rawn JD, Aranki SF, Couper GS, et al. Modern surgical treatment of massive pulmonary embolism: results in 47 consecutive patients after rapid diagnosis and aggressive surgical approach. *J Thorac Cardiovasc Surg*. 2005 May;129(5):1018-23.